

Gonadal Evaluation in Girls

- Targeted H&P (including menstrual history)
- Review growth curve
- Bone age

History of breast development, vaginal bleeding and/or signs of estrogenization below age 8 years and/or
History of irregular menses (post-puberty)

- LH, FSH and estradiol
- Pelvic US

Ovarian cyst
+/- abnormal labs

Likely MAS-associated precocious puberty

Normal US +/- abnormal labs

Possible MAS-associated precocious puberty

No history of breast development, vaginal bleeding and/or signs of estrogenization below age 8 years

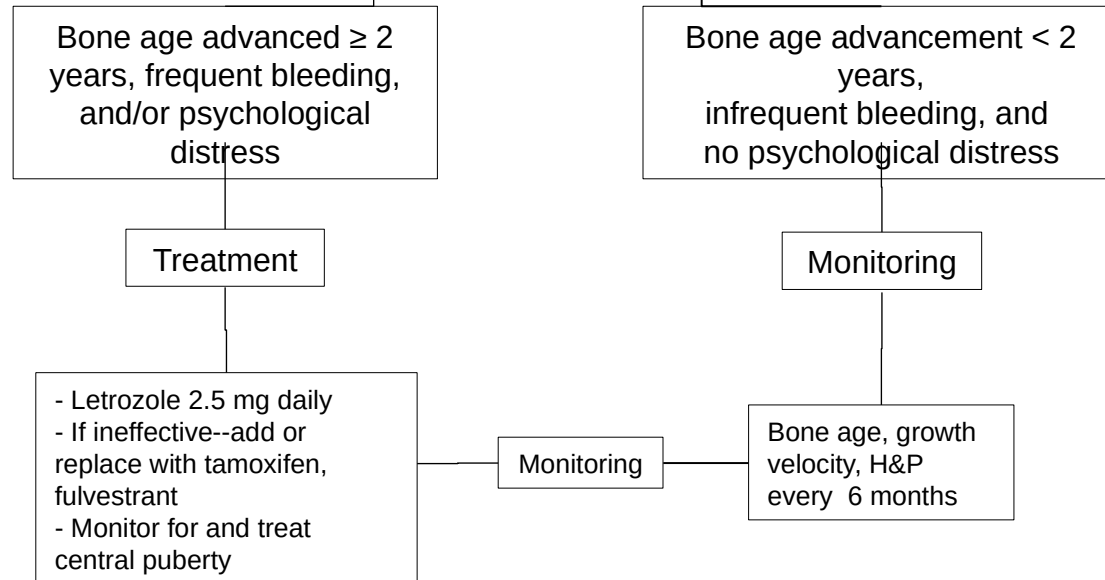
Bone age advancement \geq 2 years

- Possible MAS-associated precocious puberty
- Consider other MAS-associated endocrinopathies

No bone age advancement

MAS-associated precocious puberty unlikely

Precocious puberty management in girls



Gonadal Evaluation in Boys and Men

- Targeted H&P (including testicular volume)
- Review growth curve (children)
- Bone age (children)
- Testicular US (at baseline and after age 5)

Abnormal US and/or macro-orchidism

Normal US, no macro-orchidism

Likely MAS-associated testicular involvement

MAS-associated testicular involvement unlikely

Suspicion for precocious puberty (based on physical exam, growth acceleration, bone age advancement): LH, FSH, testosterone

Elevated testosterone +/- bone age advancement

Normal labs, bone age advancement ≥ 2 years

Normal labs, no bone age advancement

Likely MAS-associated precocious puberty

- Possible MAS-associated precocious puberty
- Consider other MAS-associated endocrinopathies

No MAS-associated precocious puberty

Gonadal involvement management in boys and men

Precocious puberty (boys)

Bone age advanced ≥ 2 years

Treatment

- Combination testosterone blocker and aromatase inhibitor
- Monitor for and treat central puberty

Bone age advancement < 2 years

Monitoring

- Bone age, growth velocity, H&P every 6 months

Monitoring

Ultrasound abnormalities only (boys and men)

- Testicular physical exam yearly
- US for lesions that are palpable or increasing in size
- Consider biopsy for palpable mass, large and/or progressive lesions

Thyroid Evaluation

Children

- Targeted H&P
- Review growth curve (children)
- T3, free T4, TSH
- Thyroid US

Adults

- Targeted H&P
- T3, free T4, TSH
- Thyroid US only if abnormal thyroid physical exam

Abnormal US, low TSH, elevated free T4 or T3, T3/T4 ratio >20

MAS-associated hyperthyroidism

Abnormal US, normal thyroid function tests

Subclinical thyroid involvement

Normal US, normal thyroid function tests

No thyroid involvement

All patients:

- Thyroid exam yearly
- Thyroid US yearly
- Consider biopsy or removal of lesions with concerning appearance

Age ≤ 10 years:

- Thyroid function tests every 6-12 months
- Physical examination, growth velocity every 6 months

Hyperthyroidism Management

```
graph TD; A[Hyperthyroidism Management] --> B[Short-term management: - Carbimazole or Methimazole]; A --> C[Long-term management: - Total thyroidectomy or - Radioablation]; C --> D[Monitor thyroid function tests and periodic thyroid US due to possibility of tissue regrowth];
```

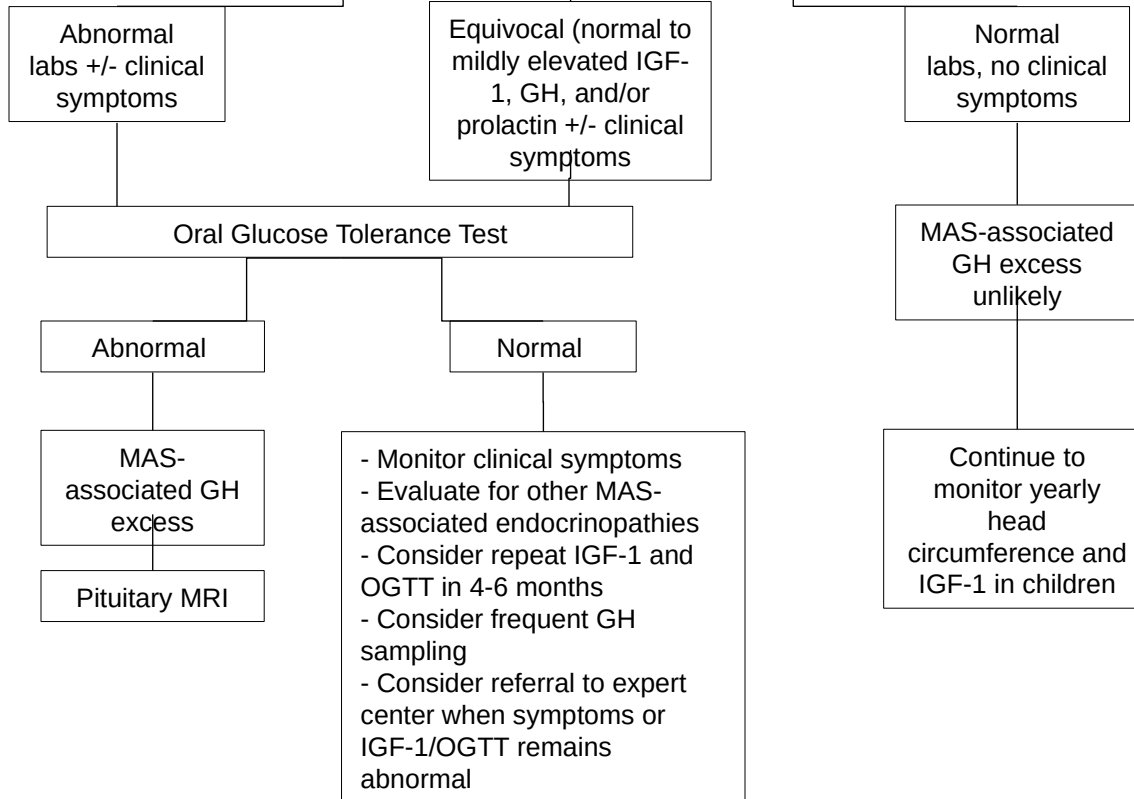
Short-term management:
- Carbimazole or
Methimazole

Long-term management:
- Total thyroidectomy or
- Radioablation

Monitor thyroid function tests and
periodic thyroid US due to
possibility of tissue regrowth

Growth Hormone Excess evaluation

- Targeted H&P (including height measurement and comparison to midparental)
- Review growth curve (children)
- Bone age (children)
- IGF-1, GH, prolactin



Growth Hormone excess management

Medical

- Somatostatin analogs
- Pegvisomant
- Dopamine agonist (for mild disease)
- Used alone or in combination

Surgical

- For patients inadequately responsive to medical therapy
- Total hypophysectomy typically required

Radiotherapy

- Controversial due to increased sarcomatous transformation of craniofacial FD
- Frequently ineffective
- Final recourse for severe disease resistant to medications AND poor surgical candidates only after consultation with referral center

Treatment Goal: IGF-1 Z-score between -2 and +1.

Adrenal Evaluation (children)

- Targeted H&P (hypertension, facial plethora, hirsutism, abdominal obesity, developmental delay, failure to thrive, small for gestational age)
- Review growth curve

High suspicion for hypercortisolism

- 24 hour urinary free cortisol
- Low dose dexamethasone suppression test
- Diurnal cortisol (may not be useful less than ~ 1 year of age)
- Chemistry panel (evaluate for hypokalemia, hyperglycemia, transaminemia)
- Adrenal CT
- Renal US (nephrocalcinosis)
- Echocardiogram

Low suspicion for hypercortisolism

Age \leq 3 years

- Small potential for future hypercortisolism
- Growth velocity, H&P every 6 months

Age $>$ 3 years

Future hypercortisolism unlikely

Hypercortisolism Management

Short-term management

Metyrapone –First line
Etomidate- For critically ill
patients unstable for surgery
-Others: mitotane,
ketoconazole

Long-term management

Adrenalectomy

- Bilateral adrenalectomy
- Spontaneous resolution seen in approx. one third—consider watchful waiting in patients with mild disease
- Monitor cognitive development